Case report

Vascular leiomyoma of the nasal cavity: case report

Chih-Jung Chen, Ming-Tang Lai, Chia-Yuen Chen and Chia-Lang Fang

Keywords: *vascular leiomyoma; nasal cavity; Epstein-Barr virus; immunocompromised patients; sex hormones*

Vascular leiomyomas are extremely rare in the nasal cavity, accounting for less than 1% of all vascular leiomyomas.[1] The association of Epstein-Barr virus (EBV) with smooth muscle tumors in immunocompromised patients is well established.[2] The geographic distributions of EBV infection and nasopharyngeal carcinoma in China and the close proximity of the sinonasal area to the nasopharynx raise the possibility that EBV may be involved in the pathogenesis of nasal smooth muscle tumors. Herein, we report a case of vascular leiomyoma of the nasal cavity in an 88-year-old man and discuss the role of sex hormones in tumorigenesis and a possible relationship with EBV infection.

CASE REPORT

An 88-year-old man suffered from right-side hearing impairment and purulent discharge in the bilateral nasal cavities for several months. He visited Taipei Municipal Wan Fang Hospital, where the physical examination revealed a 1.5-cm-diameter tumor in the right nasal cavity. The computed tomographic (CT) scan showed a nodular lesion about 9.3 mm×9.0 mm×8.0 mm in the anterior and medial aspects of the right inferior nasal turbinate (Fig. 1). Total excision of the tumor was performed. The postoperative course was uneventful. There was no local recurrence or metastasis in a 12-month follow-up period.

The specimen submitted for pathological examination consisted of one tissue fragment measuring 1.3 mm× 1.2 mm×0.7 cm. Grossly, it was polypoid and well circumscribed with a grayish-tan, elastic cut surface covered by nasal mucosa. Microscopically, the tumor was composed of smooth muscle cells growing in fascicles in the submucosa (Fig. 2). No mitotic figure or significant nuclear atypia was observed in the tumor cells. There was proliferation of thick-walled blood vessels in the tumor. Focal fatty metaplasia was seen (Fig. 3). No tumor necrosis or hemorrhage was found. The overlying nasal mucosa revealed focal erosion and dense lymphocyte infiltration. Immunohistochemical studies with a panel of antibodies including smooth muscle actin, desmin, CD34, estrogen receptor (ER), and progesterone receptor (PR) were performed using an autostaining system (Ventana Medical System, Inc., Arizona, USA). The tumor was diffusely positive for smooth muscle actin (Fig. 4) and desmin, and negative for CD34, ER, and PR. Formalin-fixed paraffin-embedded tissue was analyzed for EBV mRNA using *in situ* hybridization of an EBER1-specific antisense oligoprobe (a digoxigenin-labeled 30-base oligonucleotide antisense probe). The EBV *in situ* hybridization study revealed negative results in the tumor cells.

Fig. 1. Non-contrast axial CT scan of the paranasal sinuses reveals a polypoid soft tissue nodule (arrow) protruding from the anterior and medial aspects of the right inferior nasal turbinate.

DISCUSSION

Vascular leiomyomas of the nasal cavity are extremely rare. Hachisuga et al studied 562 cases of vascular leiomyoma and only 5 tumors were located in the nasal cavity.[1] In the sinonasal area and nasopharynx, non-epithelial neoplasms are less common than epithelial neoplasms, and constitute only about 10%−20% of all tumors at this location.[3] The clinical presentation of sinonasal non-epithelial neoplasms is similar to that seen in epithelial neoplasms. No specific findings can be identified on physical and radiological examinations in the majority of cases. A correct diagnosis can definitively be made by a histological examination of the excised tumor.[4]

Department of Pathology (Chen CJ and Fang CL), Department of Otolaryngology (Lai MT), Department of Radiology (Chen CY), Taipei Municipal Wan Fang Hospital, Taipei, China
Department of Pathology, Taipei Medical University, Taipei 110, China (Fang CL)
Correspondence to: Dr. Chia-Lang Fang, Department of Pathology, Taipei Medical University, Taipei 110, China (Tel: 886-2-27382126. Fax: 886-2-23770054. Email: ccllfang@tmu. edu.tw)

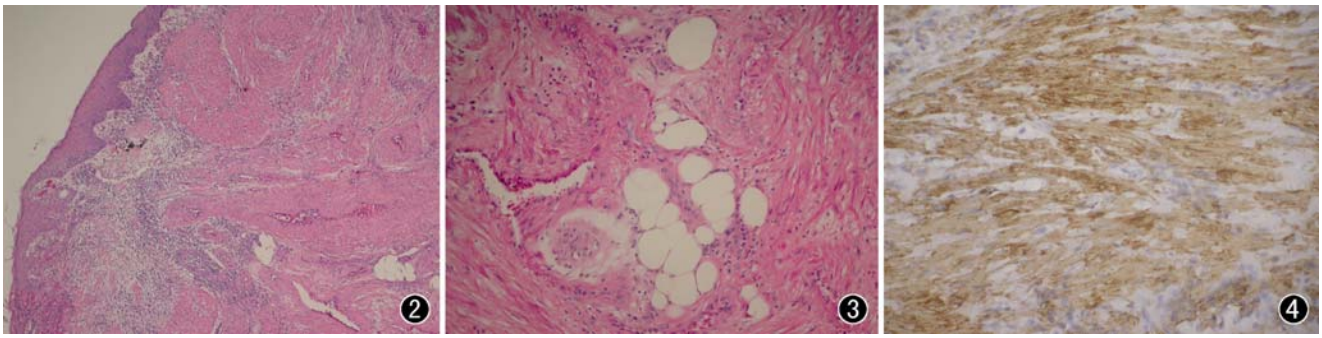

Fig. 2. The submucosal tumor is composed of abundant thick-walled blood vessels blending with proliferative smooth muscle tissue (HE, original magnification × 40).
Fig. 3. Focal fatty metaplasia is visible in the tumor (HE, original magnification × 100).
Fig. 4. The tumor cells show positive immunoreactivity of smooth muscle actin (ABC method, original magnification × 200).

Vascular leiomyoma of the nasal cavity was first described by Maesaka et al in 1966.[5] Since then, this entity has been reported in a few papers of one or a few cases. To the time of this writing, fewer than 60 cases of vascular leiomyoma of the nasal cavity had been reported in the English literature. Huang and Antonescu proposed the histological parameters of sinonasal smooth muscle tumors to correlate and predict the clinical behavior. The tumors are subdivided into leiomyomas, smooth muscle tumors of uncertain malignant potential (SMTUMP), and leiomyosarcomas.[6] Vascular leiomyomas of the nasal cavity are usually solitary, small (with a mean diameter of 2.0 cm), predominant in females (with a female: male ratio of about 3.75: 1), and relatively common in middle age (at a mean age of 40 years).[3-5] The most common clinical manifestations are epistaxis and nasal obstruction. Most authors believe that vascular leiomyomas of the nasal cavity arise from blood vessels.

Hormone receptors may play a role in the tumorigenesis of extrauterine smooth muscle tumors, like the uterine counterparts. Marioni et al documented a case of a nasal vascular leiomyoma which was positive for PR and negative for ER by an immunohistochemical study.[7] However, Kim et al reported a case of a nasal vascular leiomyoma in a female patient with negative immunoreactivity to both ER and PR.[8] In the present case, the immunohistochemical study demonstrated that neither ER nor PR was expressed in the tumor. Sex hormone dependence is still controversial in nasal vascular leiomyomas. More studies are needed to clarify the influence and mechanism of sex hormones on this tumor.

EBV infection is common in far eastern Asia including Japan and southern China, where EBV-associated tumors of the head and neck are often documented. Although the true incidence and prevalence are unknown, sinonasal vascular leiomyomas have more commonly been reported in Asian countries such as Japan, Korea and China.[1,4-6,8,9] EBV-associated smooth muscle tumors have been documented in immunocompromised patients including AIDS patients and patients undergoing organ transplantation. EBV-associated smooth muscle tumors are typically well differentiated with little atypia and usually low mitotic count.[2] The study of the association between sinonasal vascular leiomyomas and EBV infection has never been conducted. The geographic distributions of EBV infection and nasopharyngeal carcinoma in China, the close proximity of the sinonasal area to the nasopharynx, and the well-established association of EBV infection and smooth muscle tumors in immunocompromised patients raise the possibility that EBV may be involved in the tumorigenesis of nasal smooth muscle tumors. The patient in our case is an elderly Taiwanese man with no underlying immunodeficiency. However, his immune function could have been impaired by the aging process. In our case, no evidence of EBV infection was found by EBER1 *in situ* hybridization.

We report a rare vascular leiomyoma of the nasal cavity with the unusual clinical presentation of ipsilateral hearing impairment, which has never been described in previous cases. Unlike previously published cases which usually occurred in middle-aged women, the patient reported here is an elderly man. Neither ER nor PR was expressed in this case. The negative EBER1 result indicates no association with EBV infection. The roles of sex hormones and EBV infection in the tumorigenesis of nasal vascular leiomyomas should be clarified. Further studies on a large scale with more cases are needed.

REFERENCES

1. Hachisuga T, Hashimoto H, Enjoji M. Angioleiomyoma. A clinicopathologic reappraisal of 562 cases. Cancer 1984; 54: 126-130.
2. Deyrup AT, Lee VK, Hill CE, Cheuk W, Toh HC, Kesavan S, et al. Epstein-Barr virus-associated smooth muscle tumors are distinctive mesenchymal tumors reflecting multiple infection events: a clinicopathologic and molecular analysis of 29 tumors from 19 patients. Am J Surg Pathol 2006; 30: 75-82.
3. Fu YS, Wenig BM, Abemayer E, Wenig BL. Head and neck pathology with clinical correlation. In: Fu YS, Perzin KH, Eds. Pathology of the nasal cavity, paranasal sinuses and nasopharynx. New York: Churchill Livingstone; 2001:

185-188, 194-196.
4. Wang CP, Chang YL, Sheen TS. Vascular leiomyoma of the head and neck. Laryngoscope 2004; 114: 661-665.
5. Maesaka A, Keyaki Y, Nakahashi T. Nasal angioleiomyoma and leiomyosarcoma-report of 2 cases. Otologia (Fukuoka) 1966; 12: 42-47.
6. Huang HY, Antonescu CR. Sinonasal smooth muscle cell tumors: a clinicopathologic and immunohistochemical analysis of 12 cases with emphasis on the low-grade end of the spectrum. Arch Pathol Lab Med 2003; 127: 297-304.
7. Marioni G, Marchese-Ragona R, Fernandez S, Bruzon J, Marino F, Staffieri A. Progesterone receptor expression in angioleiomyoma of the nasal cavity. Acta Otolaryngol 2002; 122: 408-412.
8. Kim SJ, Hong SH, Roh MS. Angioleiomyoma of the nasal cavity: a case report. Korean J Pathol 2004; 38: 181-183.
9. Murono S, Ohmura T, Sugimori S, Furukawa M. Vascular leiomyoma with abundant adipose cells of the nasal cavity. Am J Otolaryngol 1998; 19: 50-53.

(Received May 17, 2006)
Edited by GUO Li-shao